

**CASE REPORT**

## **Liver abscess associated with an oral flora bacterium *Streptococcus anginosus***

Hava Yılmaz<sup>1</sup>, Esmeray Mutlu Yılmaz<sup>1</sup>, Adil Karadağ<sup>2</sup>, Saban Esen<sup>1</sup>, Mustafa Sunbul<sup>1</sup>, Hakan Leblebicioglu<sup>1</sup>

<sup>1</sup>Department of Infectious Diseases and Clinical Microbiology, Medical School, Ondokuz Mayıs University, Samsun, Turkey

<sup>2</sup>Department of Microbiology and Clinical Microbiology, Medical School, Ondokuz Mayıs University, Samsun, Turkey

### **ABSTRACT**

Viridans group *Streptococcus*, a bacterium of the oral flora has a low-virulence and rarely causes liver abscess. A 40-year-old male patient was admitted to the hospital complaining of high fever and malaise. A physical examination revealed poor oral hygiene; there were caries on many teeth, and he had hepatomegaly. A hepatic abscess was identified in his abdominal tomography. *Streptococcus anginosus* was isolated from the drainage material, and the bile ducts were normal in his MRI cholangiography. An immunocompetent case of liver abscess caused by *Streptococcus anginosus* originated most probably from oral flora is presented here. *J Microbiol Infect Dis* 2012; 2(1):33-35

**Key words:** Liver abscess, *Streptococcus anginosus*, oral flora, bacteremia

### **Bir oral flora bakterisi olan *Streptococcus anginosus* ile olan karaciğer absesi**

#### **ÖZET**

Oral flora bakterisi olan düşük virülanslı viridians streptokoklar nadiren karaciğer absesine sebep olurlar. Kırk yaşında erkek hasta yüksek ateş ve halsizlik şikayeti ile hastaneye başvurdu. Fizik muayenesinde oral hijyeni kötü ve çok sayıda çürük dişi ile hepatomegalisi vardı. Batın tomografide karaciğerde abse görüldü. Absenin drenaj materyalinde *Streptococcus anginosus* izole edildi, MR kolanjiyografisinde safra yolları doğaldı. Bu yazıda immünkompetan hastada büyük olasılıkla oral flora kaynaklı *Streptococcus anginosus*'un etken olduğu karaciğer absesi olgusu sunuldu.

**Anahtar kelimeler:** Karaciğer absesi, *Streptococcus anginosus*, oral flora, bakteremi

#### **INTRODUCTION**

Pyogenic liver abscess rarely occurs in healthy immunocompetent adults. The pyogenic liver abscess associated with the oral flora bacterium *Streptococcus anginosus* was first reported in 1975. Studies conducted during the following years show that *S. anginosus* is the most common cause of hepatic abscess; however, it was only reported a few times during the following years.<sup>1,2</sup> *S. anginosus* is a sub-group of viridans streptococcus, and it's one of the bacteria in the natural flora of the respiratory, gastrointestinal, and urogenital systems.<sup>1</sup> They generally cause purulent infections with abscess. *S. anginosus* infections are uncommon in healthy individuals. The most common etiology (42%) of hepatic abscess is bile duct diseases.<sup>3,4</sup> There is few published literature about the hepatic abscess associated with dental problems or dental treatments.<sup>4-6</sup>

#### **CASE**

A 40-year-old male patient was admitted to the hospital, complaining of high fever and malaise lasting for a week. He had previously been given ciprofloxacin for a urinary infection during hospitalization at another center. The ciprofloxacin was replaced by imipenem, since the fever was still continuing. He was referred to our hospital due to thrombocytopenia and increased hepatic enzymes with a presumed diagnosis of Crimean-Congo Hemorrhagic Fever (CCHF). He had prominent shaking chills and higher fever in the evenings. Night sweats, headache, and constipation symptoms were noted in his questioning. He drank alcohol every day for 20 years but had no known diseases. Following are the results of his physical examination: temperature, 37.8°C; pulse, 112/minute; respiration, 36/minute; and

**Correspondence:** Dr. Hava Yılmaz

Ondokuz Mayıs University, Samsun, Turkey Email: hyilmaz@omu.edu.tr

Received: 27 January, 2012, Accepted: 10 March, 2012

Copyright © Journal of Microbiology and Infectious Diseases 2012, All rights reserved

blood pressure, 140/80 mmHg. His oral hygiene was poor; there were caries on many teeth. Respiratory sounds were normal, with no additional murmurs found. The patient had no abdominal pain or defense. His liver was palpated four centimeters below the costal margin. The other system examination was normal.

The results of his laboratory tests are as follows: Hb, 13.6 g/dl; leucocytes, 11600 /mm<sup>3</sup>; neutrophils, 90%; thrombocytes, 280,000/mm<sup>3</sup>; aspartate aminotransferase (AST), 400 U/L; alanine aminotransferase (ALT), 408 U/L; total bilirubin, 2 mg/dL; direct bilirubin, 1.4 mg/dL; sedimentation, 80 mm/hour; and C-reactive protein, 308 mg/L. Human immunodeficiency virus (HIV), hepatitis B and C, CMV and EBV serologies were negative.

No pathology was found in the chest radiography. CCHF PCR-RNA was negative. Unexpected respiratory distress and tachycardia had developed, and rhoncus and wheezing in the right hemithorax were found during auscultation. No lung pathology was found in his urgent chest tomography; however, an abscess (9.5 x 6 cm) was found in the left lobe of the liver (Figure 1). As a result, an empirical ampicillin/sulbactam IV was initiated. *Entamoeba histolytica* serology was negative. We drained 550 cc of hemopurulent exudate by interventional ultrasonography. *Streptococcus anginosus* was cultured in the exudate and blood cultures. *Streptococcus anginosus* was identified by the VITEK automated system. Antibiotic sensitivity was performed with the disc diffusion technique. It was sensitive to penicillin. Since the patient still had a fever by the 18th day of the treatment, another 300 cc exudate was drained by interventional ultrasonography. It was observed in the abdominal CT that the size of the abscess had decreased to 6.5 cm by the 21st day of the treatment (Figure 2). The nose, ear, lung, and gastrointestinal system infections were excluded clinically. No findings associated with endocarditis were found by transthoracic and transesophageal echocardiography. The bile ducts were normal in MRI cholangiography.

The patient was asymptomatic on the 30th day of the treatment. The drainage catheter was removed, oral sequential amoxicillin clavulanic acid was given, and the patient was discharged.

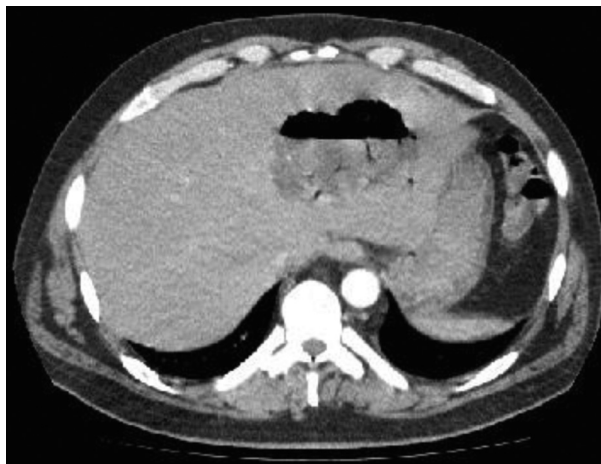

Figure 1. Hepatic abscess in the thorax CT

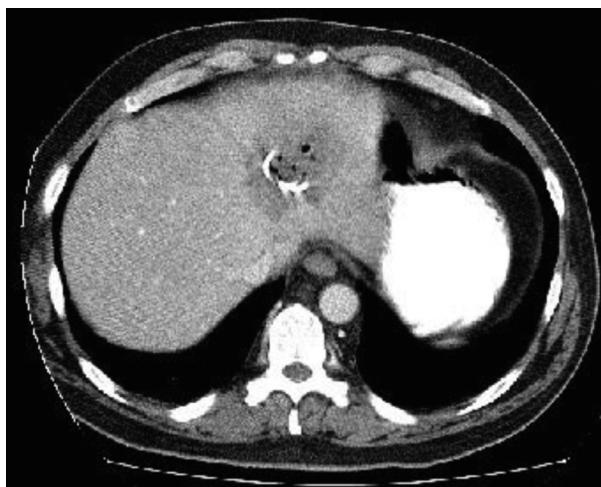


Figure 2. Abscess and drainage catheter are seen in the CT performed at the 21st day of the treatment.

## DISCUSSION

An immunocompetent case of bacteremia and liver abscess associated with the oral flora bacteria *Streptococcus anginosus* is presented here. There are many reports of organ abscess associated with oral infections, poor oral hygiene, and tooth problems. The patient had not been treated for tooth problems recently. There were, however, caries on many teeth. He frequently drinks alcohol, and brushes his teeth irregularly. It's been reported by several studies that a bacteremia which may develop following inadequate oral hygiene, such as in this situation, may cause hepatic abscesses.<sup>7,8</sup> Viridans streptococci are considered to have low virulence, since they do not release exotoxin or endotoxin. The hydrolytic enzymes they release, such as hyaluronidase

and sialidase, are responsible for the pathogenesis. These enzymes cause tissue destruction. *S. anginosus* is a sub-group of viridans streptococcus, and contrary to other viridans streptococcus, they generally cause purulent infections with abscess. It's known that the capsule of *S. anginosus* protects the microorganism against phagocytosis, and provides an environment suitable for proliferation, following adhesion to the damaged tissues.<sup>9</sup>

Most pyogenic hepatic abscesses are associated with biliary or intestinal systems. The most common cause is obstruction of bile ducts. The most common comorbidity is diabetes. Additionally, the risk of hepatic abscesses is higher in patients with immunodeficiency, sickle cell anemia, malignancy, and hepatic transplantation when compared with the normal population.<sup>3,4,6</sup>

Generally, bacteremia does not occur with hepatic abscesses. The systemic problems are more common in older patients, patients with HIV infections, and chemotherapy and radiotherapy patients. The risk factors associated with bacteremia are diabetes, cancer, severe immunosuppression, severe neutropenia, prophylactic quinolone, trimethoprim-sulfamethoxazole and H2 receptor antagonists use, oral mucositis, and IV catheters.<sup>5</sup> No other diseases apart from chronic alcoholism or immunosuppression were observed.

Liver abscesses developed rarely; however, they are life-threatening infections.<sup>3,6,10</sup> The liver abscess associated with *S. anginosus* is generally (78%) monomicrobial, as compared to the liver abscess associated with other microorganisms.<sup>3</sup> The duration of the symptoms are longer in a liver abscess associated with *S. anginosus* than the liver abscess associated with other microorganisms. The complications and the outcomes of these hepatic abscesses, however, are not different from each other.<sup>2</sup>

The oral cavity contains more than 500 bacteria. Oral infections including gingivitis and tooth abscesses following the destruction of mucosal integrity due to poor oral hygiene may cause dissemination of oral microorganisms into the blood and may result in infections all over the body. The microorganism may reach the liver through the hepatic artery,<sup>5,6</sup> which may explain the pathogenesis. It is assumed that the etiology of the abscess is due to poor oral hygiene. *S. angino-*

*sus* infections generally occur as deep organ abscesses. Treatment includes antibiotherapy and surgical drainage.

CCHF was initially suggested due to the fever, thrombocytopenia, increased hepatic enzymes, and the summertime admission during in an endemic region. Since there is no acarid and hemorrhage history, however, and since the high fever was observed once per day, the CCHF probability was lower. CCHF was ruled out since PCR CCHF-RNA was negative.

In conclusion, tooth disease and tooth treatments rarely cause hepatic abscess.<sup>4</sup> The incidence is lower in patients without immunosuppressive conditions, and bile ducts and gastrointestinal pathologies. It should be remembered that the oral flora bacteria *S. anginosus-mitis* group may cause transient bacteremia and lead to deep organ abscess in patients with poor oral hygiene; the agents against *S. anginosus* should be used for empirical therapy of the pyogenic hepatic abscess developed in these cases.

## REFERENCES

1. McKenzie TJ, Lillegard JB, Grotz TE, Moir CR, Ishitani MB. Pyogenic liver abscess secondary to *Streptococcus anginosus* in an adolescent. *J Pediatr Surg* 2010;45:15-17.
2. Tran MP, Caldwell-McMillan M, Khalife W, Young VB. Streptococcus intermedius causing infective endocarditis and abscesses: a report of three cases and review of the literature. *BMC Infect Dis* 2008;8:154.
3. Corredoira J, Casariego E, Moreno C, et al. Prospective study of *Streptococcus milleri* hepatic abscess. *Eur J Clin Microbiol Infect Dis* 1998;17:556-560.
4. Schiff E, Pick N, Oliven A, Odeh M. Multiple liver abscesses after dental treatment. *J Clin Gastroenterol* 2003;36:369-371.
5. Gendron R, Grenier D, Maheu-Robert L. The oral cavity as a reservoir of bacterial pathogens for focal infections. *Microbes Infect* 2000;2:897-906.
6. Huang CJ, Pitt HA, Lipsett PA, et al. Pyogenic hepatic abscess. Changing trends over 42 years. *Ann Surg* 1996;223:600-607.
7. Petti CA, Stratton IV CW. *Streptococcus anginosus* group. In: Mandell G, Bennett J, Dolin R, eds. Principles and practice of infectious diseases, 7th edn. Philadelphia: Churchill Livingstone. 2010: 2681-2685.
8. Wagner KW, Schon R, Schumacher M, Schmelzeisen R, Schulze D. Case report: brain and liver abscesses caused by oral infection with *Streptococcus intermedius*. *Oral Surg Oral Med Oral Pathol Oral Radiol Endod* 2006;102:21-23.
9. Sinner SW, Tunkel AR. Viridans streptococci, groups C and G streptococci, and *Gemella* species. In: Mandell G, Bennett J, Dolin R, eds. Principles and practice of infectious diseases, 7th edn. Philadelphia: Churchill Livingstone, 2010: 2667-2680.
10. Rodrigues AL, Soares MC, Ramos FL, Crociati Meguins L. Multiple pyogenic liver abscesses caused by *Streptococcus constellatus* in the Amazon region. Case report. *Ann Hepatol* 2009;8:255-257.