

RESEARCH ARTICLE

Mycological and Serological Study of Invasive Aspergillosis in A Tertiary Care Hospital

Sumanpreet Kaur, Veenu Gupta, Deepinder Kaur Chhina, Akashdeep Singh, Daaman Sharma

Department of Microbiology, Dayanand Medical College & Hospital, Ludhiana, Punjab, India

ABSTRACT

Objectives: Invasive aspergillosis (IA) has emerged as a major life threatening infection in high risk patients. Recent advances have led to early diagnosis of IA by detecting *Aspergillus* antigens in serum particularly Galactomannan (GM). Objective of the study was to correlate fungal smear, culture and Galactomannan assay in patients with suspected IA and to categorize them into “proven,” “probable,” and “possible,” cases as per European Organization for Research and Treatment of Cancer and Mycoses study group case definitions (EORTC/MSG) criteria.

Methods: The prospective study was conducted over a period of one year in the department of Microbiology, Dayanand Medical College and Hospital, Ludhiana. A total of 319 patients with suspicion of IA were included in the study. GM antigen detection test was done from serum samples. KOH mount was done and samples were inoculated on Sabouraud's dextrose agar (SDA). Growth obtained was analyzed as per standard protocol.

Results: GM assay positivity among suspected patients of IA was 47%. The mean age group affected was 51.8 years (51.8±15.2) and majority was males (78.1%). The patients were categorized as Proven IA (0%), Probable IA (52.7%), Possible IA (41.4%) and No IA (5.9%). *Aspergillus flavus* was the most common isolate (77.4%)

Conclusion: The study demonstrated that serological tests have an edge over routine smear and culture for the diagnosis of invasive aspergillosis. Thus, Galactomannan assay is a useful diagnostic for early detection of IA in high risk patients. *J Microbiol Infect Dis* 2018; 8(1):8-12

Keywords: Galactomannan assay, Invasive aspergillosis, Fungal culture, Fungal smear

INTRODUCTION

Aspergillus infections in humans were first described in eighteenth century. The genus *Aspergillus* receives its name due to resemblance to an “aspergillum” used to sprinkle holy water [1]. Of the recognized species of this genus, twenty species have been verified to cause human infection and three of them are frequently encountered which are *Aspergillus fumigatus*, *A. flavus* and *A. niger*.

The spectrum of *Aspergillus* associated respiratory disorder comprises three categories: allergic manifestations, saprophytic colonization of the respiratory tract and invasive disease [2]. Invasive aspergillosis is a major cause of morbidity and mortality in immunosuppressed patients [3].

Aspergillus species enter the host most commonly through the lungs by the inhalation of conidia [1]. However, infection has also been reported by exposure and inhalation of water aerosols contaminated with *Aspergillus* conidia [4]. The host factors that are responsible for the increased risk of IA are recent history of neutropenia, receipt of an allogeneic stem cell transplant, prolonged use of corticosteroids, treatment with immunosuppressants, solid organ transplant recipients, immunocompromised patients of any etiology presenting with persistent fever despite first line antibiotic therapy or with suspected pulmonary infection based on clinical signs and symptoms, or new chest X-ray abnormalities; and those suffering from HIV infection [5].

Correspondence: Dr. Sumanpreet Kaur, Department of Microbiology, Dayanand Medical College & Hospital, Tagore Nagar, Ludhiana, Punjab-141001, India
E-mail: Sumanpreetkaur87@gmail.com

Received: 22 February 2017 Accepted: 31 December 2017

Copyright © JMID / Journal of Microbiology and Infectious Diseases 2018, All rights reserved

The clinical manifestations of aspergillosis are dependent upon the site and severity of involvement and the host immune status. *Aspergillus* has been reported involving all organ sites but the upper airways, lungs and surrounding structures are those most frequently involved.

The gold standard in the diagnosis of IPA is histopathological examination of lung tissue [6]. One of the approach to diagnose IA is to examine appropriate specimens microscopically as wet mount preparation with or without addition of 10% KOH. Fungal culture enables the diagnosis of invasive aspergillosis. But there has been a great interest in nonculture-based techniques such as the detection of Galactomannan, β -D-glucan and DNA by PCR-based methods [7].

Characteristic CT findings in angioinvasive aspergillosis consist of nodules surrounded by a halo of ground-glass attenuation ("halo sign") or pleura-based, wedge-shaped areas of consolidation [8].

The treatment of invasive aspergillosis is difficult. Empiric therapy should be started as soon as there is clinical suspicion. Amphotericin B has been the first line of therapy for IA [9]. A broad-spectrum triazole, voriconazole, has been approved as the initial treatment of invasive aspergillosis and is currently considered the treatment of choice in many patients with IA [10].

In light of the above, this study determined the utility of GM assay in diagnosis of IA in high-risk patients and to correlate Galactomannan assay with fungal smear and culture from relevant samples along with clinical data.

METHODS

This was a prospective study conducted over a period of one year (1st April 2015 to 31st March 2016) in the Department of Microbiology, Dayanand Medical College and Hospital, Ludhiana, Punjab, India. Details of patients including epidemiological data, provisional clinical diagnosis, risk factors, treatment history, Hemogram, radiological, histopathological and microbiological evaluation (Galactomannan assay, fungal smear/culture) and outcome were recorded. Eligible and suspected patients displayed at least one of the following host factors: immunocompromised patients,

persistent fever despite first line antibiotic therapy, suspected pulmonary infection based on clinical signs and symptoms, or new chest X-ray abnormalities, malignancy and patients on chemotherapy within the last 3 months, neutropenia (<500 cells/ml), haemopoietic Stem Cell Transplantation (HSCT), solid organ transplant recipients, chronic steroid use, those suffering with HIV infection.

Samples

Serum samples collected in plain vials were evaluated for the presence of GM antigen. Relevant samples from the respiratory tract (sputum, bronchoalveolar lavage, endotracheal secretions), biopsy specimens and sterile body fluids were collected in sterile, leak-proof and screw-capped container under all aseptic precautions and were also evaluated for presence of *Aspergillus spp.* by microscopy and culture on Sabouraud's dextrose agar incubated at 37 °C and 25 °C for a maximum period of 4 weeks. A positive sample showed the presence of septate hyphae with classical acute angle branching. The growth obtained was identified on the basis of colony morphology, pigment production and Lactophenol Cotton Blue (LCB) preparation. Culture was positive if it showed growth resembling *Aspergillus spp.* Data collected was analyzed using descriptive statistical method.

RESULTS

In the present study, out of a total 319 patients of suspected invasive aspergillosis, 249 (78.1%) patients were males and 70 (21.9%) were females. Suspected patients of invasive aspergillosis were most commonly seen in the age group of 31-45 years. The mean age group affected was 51.8 years with standard deviation of 15.2 (51.8 \pm 15.2).

Galactomannan assay positivity among suspected patients of invasive aspergillosis was 47 %. Out of 319 samples, 70 (21.9%) showed positive fungal smear findings and 62 (19.4%) showed fungal growth of *Aspergillus* species. (Figure 1) Out of 62 *Aspergillus* species most common species isolated was *A. flavus* (77.4%) followed by *A. fumigatus* (22.6%).

Out of 319 patients with suspicion of invasive aspergillosis, 16.3% of patients were positive both by fungal smear and culture. While 3.1%

had positive fungal culture with negative fungal smear and 5.6% of patients had only positive fungal smear (Table 1).

Out of 319 patients with suspicion of invasive aspergillosis, 15.7% of patients were positive both by Galactomannan assay and fungal culture. Positive Galactomannan assay with negative fungal culture was seen in 31.3% patients and 3.8% of patients had only positive fungal culture (Table 2).

All 319 patients with suspicion of Invasive Aspergillosis were categorized as Proven IA 0 (0%), Probable IA 168 (52.7%), Possible IA 132 (41.4%) and No IA 19 (5.9%) as per EORTC/MSG. Out of 168 patients with Probable IA, 142 showed serological/mycological evidence while 26 showed only positive mycological evidence. Mortality in suspected patients of invasive aspergillosis was 19.4% with Probable IA. Possible IA and No IA showed 25.6%, 13.6% and 5.2% mortality respectively (Table 3).

Table 1. Correlation of fungal smear with fungal culture (n=319).

Variables	Fungal culture positive (n=62)	Fungal culture negative (n=257)
Fungal smear positive (n=70)	52 (16.3%)	18 (5.6%)
Fungal smear negative (n=249)	10 (3.1%)	239 (75%)

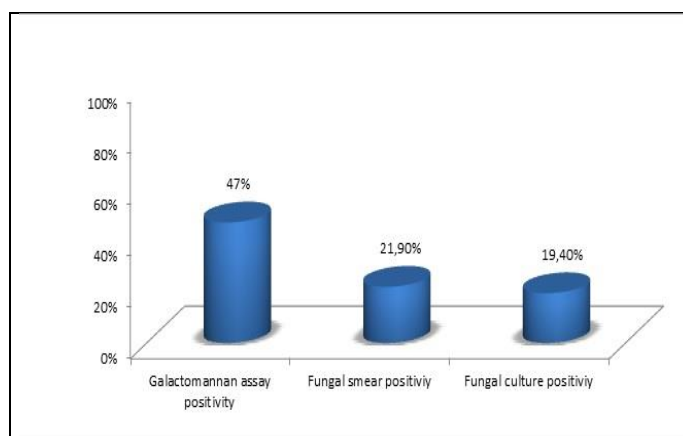
Table 2. Correlation of Galactomannan assay with fungal culture in suspected patients of invasive aspergillosis (n=319).

Galactomannan assay	Fungal Culture Positive (n=62)	Fungal Culture Negative (n=257)
GM assay Positive (n=150)	50 (15.7%)	100 (31.3%)
GM assay Negative (n=169)	12 (3.8%)	157 (49.2%)

Table 3. Patients characteristics and distribution of mycological findings based on EORTC/MSG criteria (n=319).

Patients Demographics	Probable (n=168)	Possible (n=132)	No Invasive aspergillosis (n=19)	Total (n=319)
Mean age(Range)	52.4 (16-89)	51.9 (19-85)	45.6 (25-70)	51.8 (16-89)
Sex(Male/Female)	126/42	106/26	17/3	249/70
Positive GM assay	142 (84.5%)	0 (0)	8 (42.1%)	150 (47%)
Positive Fungal smear	70 (41.7%)	0 (0)	0 (0)	70 (21.9%)
Positive Fungal culture	62 (36.9%)	0 (0)	0 (0)	62 (19.4%)
Mortality	43 (25.6%)	18 (13.6%)	1 (5.2%)	62 (19.4%)

Figure 1: Comparison of positivity of Galactomannan assay, Fungal smear and Culture in suspected patients of invasive aspergillosis (n=319).



DISCUSSION

In the present study of 319 cases of suspected invasive aspergillosis, the mean age of the patients was 51.8 ± 15.2 (range 16 y to 89 y). The similar observation was reported by Khorvash et al. In their study, mean age of the patients was found to be 54.95 ± 18.82 (range 20 y to 86 y)[11].

In our study suspected invasive aspergillosis was more common in males (78.1%) as compared to females (21.9%). This may be explained by the fact that males are maximally exposed to fungal spores particularly working with decaying vegetation like moldy hay in agriculture. These findings were consistent with the study conducted by Cordonnier et al [12] and Khanna et al [5], in which male predominance was reported. While in study by Khorvash et al females (56.1%) were more commonly affected than males (43.9%) [11].

Galactomannan assay positivity among suspected patients of invasive aspergillosis was 47 % in our study. In an another study conducted in a tertiary care center, the positive GM-ELISA was observed in 77.7% patients [5]. Although, Maertens et al reported the positive GM-ELISA in only 8.9% [13].

In present study, positive fungal smear in patients with suspicion of invasive aspergillosis was present in 21.9% while fungal culture positivity for *Aspergillus spp.* was present in 19.4% patients. In the study conducted by Cordonnier et al, positive fungal smear and culture were seen in 6.6% and 71.4% patients respectively [12].

A. flavus (77.4%) was found to be most common species isolated followed by *A. fumigatus* (22.6%) in our study. Similar observation was reported by Xess et al, in which most common species isolated was *A. flavus* (46.9%) followed by *A. fumigatus* (37.7%) [14]. While the study conducted by Subira reported *A. fumigatus* (41%) as the most common species [15].

In our study, 319 consecutive cases with suspicion of invasive aspergillosis were categorized as proven IA (0%), probable IA (52.7%), possible IA (41.4%) and no IA (5.9%) as per EORTC/MSG criteria. In a study conducted by Khanna et al, 81 patients were categorized as proven IA (14.8%), probable IA

(48.2%), possible IA (27.2%), or no IA (9.9%) [5].

Mortality in suspected patients of invasive aspergillosis was 19.4% in our study while in study conducted by Tutar et al, mortality was seen in 54.5% patients [16].

CONCLUSION

Invasive aspergillosis is a major cause of morbidity and mortality in high risk patients. Delayed diagnosis may lead to poor outcomes. The study demonstrated that Galactomannan assay is a useful diagnostic modality for early detection of invasive aspergillosis in high risk patients. Thus, this test is an early marker for invasive aspergillosis.

ACKNOWLEDGMENTS

Conflict of interest: The authors declare no personal or financial conflict of interest.

REFERENCES

1. George R, Thompson III, Thomas F. Patterson. Pulmonary Aspergillosis. *Semin Respir Crit Care Med.* 2008; 29:103-110.
2. Shah A, Panjabi C. Allergic aspergillosis of the respiratory tract. *Eur Respir Rev* 2014; 23(131):8-29.
3. Baddley JW. Clinical risk factors for invasive aspergillosis. *Med Mycol* 2011; 49:S7-S12.
4. Anaissie EJ, Stratton SL, Dignani MC, et al. Pathogenic *Aspergillus* species recovered from a hospital water system: a 3-year prospective study. *Clin Infect Dis* 2002;b34:780-789.
5. Khanna S, Oberoi JK, Datta S, Aggarwal S, Wattal C. Variables affecting the performance of Galactomannan assay in high-risk patients at a Tertiary Care Centre in India. *Indian J Med Microbiol* 2013; 31(1):34-9.
6. Ruhnke M, Böhme A, Buchheidt D, et al. Diagnosis of invasive fungal infections in hematology and oncology-guidelines of the infectious diseases working party (AGIHO) of the German society of Hematology and Oncology (DGHO). *Ann Oncol* 2012; 23:823-833.
7. Barton RC. Laboratory diagnosis of invasive aspergillosis: from diagnosis to prediction of outcome. *Scientifica* 2013:1-29.
8. Franquet T, Müller NL, Giménez A, Guembe P, de La Torre J, Bague S. Spectrum of pulmonary aspergillosis: histologic, clinical, and radiologic findings. *Radiographics.* 2001; 21:825-837.

9. Kousha M, Tadi R, Soubani AO. Pulmonary aspergillosis: a clinical review. *Eur Respir Rev* 2011; 20:156-174.
10. Herbrecht R, Denning DW, Patterson TF, et al. Voriconazole versus amphotericin B for primary therapy of invasive aspergillosis. *N Engl J Med* 2002; 347(6):408-415.
11. Khorvash F, Meidani M, Babaei L, Abbasi S, Ataei B, Yaran M. Galactomannan antigen assay from bronchoalveolar lavage fluid in diagnosis of invasive pulmonary aspergillosis in intensive care units patients. *Adv Biomed Res* 2014; 3:68-70.
12. Cordonnier C, Botterel F, Ben Amor R, Pautas C, Maury S, Kuentz M. Correlation between Galactomannan antigen levels in serum and neutrophil counts in haematological patients with invasive aspergillosis. *Clin Microbiol Infect* 2009; 15:81-86.
13. Maertens J, Eldere JV, Verhaegen J, Verbeken E, Verschakelen J, Boogaerts M. Use of circulating Galactomannan screening for early diagnosis of invasive aspergillosis in allogeneic stem cell transplant recipients. *J Infect Dis* 2002; 186:1297-1306.
14. Xess I, Mohanty S, Jain N, Banerjee U. Prevalence of *Aspergillus* species in clinical samples isolated in an Indian tertiary care hospital. *Indian J Med Sci* 2004; 58(12):513-519.
15. Subirà M, Martino R, Rovira M, Vazquez L, Serrano D, De La Cámara R. Clinical applicability of the new EORTC/MSG classification for invasive pulmonary aspergillosis in patients with hematological malignancies and autopsy-confirmed invasive aspergillosis. *Ann Hematol* 2003; 82:80-82.
16. Tutar N, Metan G, Koc AN, et al. Invasive pulmonary aspergillosis in patients with chronic obstructive pulmonary disease. *Multidiscip Respir Med* 2013; 8(1):59.