

CASE REPORT

Severe Respiratory Tract Infections with Human Bocavirus in Children

Halise Akça¹, Nilden Tuygun¹, Emine Polat², Can Demir Karacan¹

Dr. Sami Ulus Maternity, Children's Health and Diseases Training and Research Hospital, ¹Pediatric Emergency Medicine, ²Pediatrics

ABSTRACT

Acute respiratory tract infection remains a major cause of childhood hospitalization and mortality in young children. Human bocavirus (HBoV) is a virus belonging to the Parvoviridae family, which has been newly discovered to be associated with respiratory tract infection in children. Human bocavirus infection is usually seen as form of co-infection. The frequent associations of HBoV with other respiratory viruses might be explained by the persistence of HBoV in the respiratory tract. HBoV primary events generally associated with mild respiratory illness. Here, we reported three patients who developed an extremely severe acute life-threatening respiratory failure due to HBoV infection. *J Microbiol Infect Dis* 2016; 6(3): 145-147

Key words: child, human Bocavirus, respiratory tract infection

INTRODUCTION

Human Bocavirus (HBoV) is a new viral genus of the Parvoviridae family that was discovered in 2005 in upper respiratory secretions [1]. There is satisfactory evidence demonstrating an association between HBoV1 and respiratory disease in children, and there is evidence that HBoV2 (and possibly the HBoV3 and HBoV4 species) are associated with gastroenteritis [2]. The precise clinical presentation of HBoV infection remains controversial. A variety of signs and symptoms have been described in patients with HBoV infection including rhinorrhea, cough, dyspnea, wheezing, pneumonia, acute otitis media, vomiting, and diarrhea [3]. To the best of our knowledge, there is no documented case of life-threatening HBoV infection related to acute respiratory failure in previously healthy patients in Turkey. In our country, only one postmortem case report was determined HBoV infection among pediatric patients [4]. Here, three patients who developed an extremely severe acute life-threatening respiratory failure due to HBoV were described.

CASE 1

A 6-month-old male patient with acute respiratory distress including wheezing, cough and stuffiness without fever was seen. Systemic steroid, antibiotics and short acting beta-2 agonist (SABA) inhaler were commenced. In the follow up, he showed pro-

gression to respiratory distress, acidosis with total atelectasis of the left lung on chest radiography (Figure 1). Nasopharyngeal swab PCR of HBoV and RSV were both positive. He was monitored in Pediatric Intensive Care Unit (PICU). After prolonged treatment such as multiple antibiotic therapies, mechanic ventilation support, he was discharged.

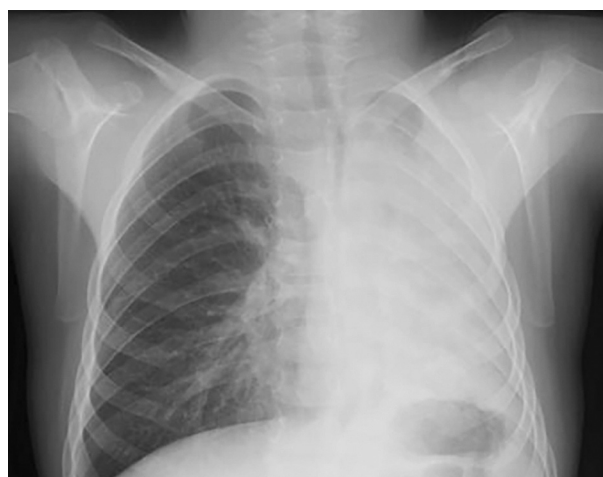

Figure 1. Chest graph of first patient

CASE 2

A 6-year-old male patient was admitted with fever, cough and tachypnea. He had long expiration time and intercostal retractions with remarkably diminished breath sounds in the left lung. Chest radio-

Correspondence: Halise Akça, Dr. Sami Ulus Children's Health and Diseases Training and Research Hospital, Altindag, Ankara, Turkey Email: haliseakca@gmail.com

Received: 08.02.2016, Accepted: 22.04.2016

Copyright © Journal of Microbiology and Infectious Diseases 2016, All rights reserved

graphs showed consolidation of the left hemithorax with air trapping (Figure 2). He was treated with antibiotics (ceftriaxone and clarithromycin) and SABA inhalation and required mechanical ventilation. *M. pneumoniae* IgM and PCR of HBoV were positive. He was fully recovered on the 10th day and discharged.

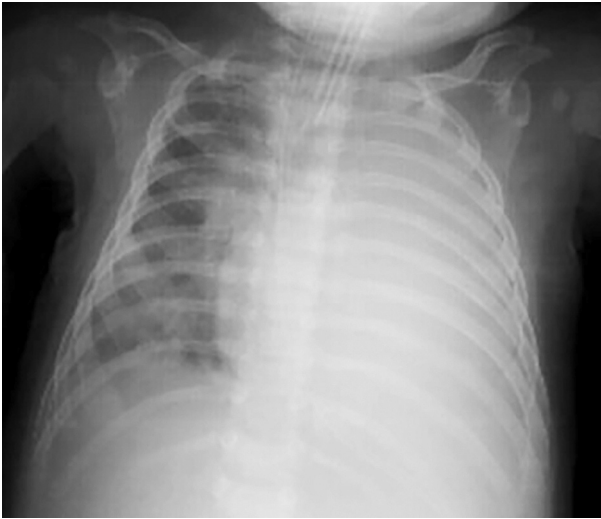


Figure 2. Chest graph of second patient

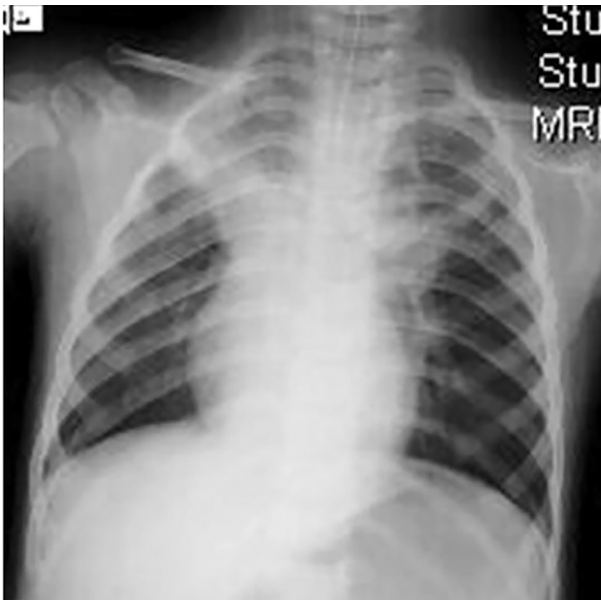

Figure 3. Chest graph of third patient

CASE 3

A 2-year-old girl who developed acute respiratory distress was admitted to the emergency department. She had bilateral rhonchus and decreased breath sounds with prolonged expiration. Parenteral antibiotic (ceftriaxone), steroid and inhalation

of SABA were initiated. Chest radiography revealed bilateral infiltrates (Figure 3). She developed severe respiratory failure despite the treatment and managed in PICU with mechanical ventilation. A nasopharyngeal aspirate was positive for HBoV by PCR. The girl was extubated on the 6th day and completely recovered on the 10th day of hospitalization.

DISCUSSION

Acute respiratory tract infection is a common disease among children requiring hospitalization. Viral agents generally play an important role in diseases pathogenesis. HBoV is a common pathogen causing viral respiratory tract infections in infants and young children.

There is a discussion about HBoV as being a pathogen that causes infection, either alone or in conjunction with other virus types. HBoV infection is usually seen as form of a co-infection in respiratory and gastrointestinal diseases [5-7]. HBoV1 has been associated with a prolonged period of persistence in the mucosa of the respiratory tract. Virus persistence plays a role in the high frequency of co-infections with proper pathogens of the upper and lower respiratory tracts. RSV has the highest frequency of HBoV1 co-infections [2]. In a study of Brieu et al., HBoV was detected in 55 (10.8%) of the 507 children with respiratory tract disease and co-infection with another virus was observed in 22 (40%) of the HBoV-positive children [8]. Calvo et al. reported 310 HBoV infections (13.5% of viral detections), and 230 of them (74%) were co-infections with other viruses in respiratory tract specimens in hospitalized children [9]. In a systematic review and meta-analysis, it was determined that HBoV was frequently detected in asymptomatic children, and so did not have significantly positive attributable fraction among the exposed in acute lower respiratory infections [10]. Overall viral co-infections do not present greater severity, but have mixed clinical features. HBoV-single infections are not significantly different from those with co-infections with respect to clinical features [9,11]. In our two patients, HBoV was determined in conjunction with other pathogens (one viral, one bacterial). In our cases, HBoV infection either single infection or co-infection with virus or bacteria showed no effect on clinical outcomes.

HBoV1 primary events generally associated with mild respiratory illness [3]. On the other hand, severe and life-threatening case reports have been documented in pediatric patients with acute respiratory distress [12,13]. Our all patients had severe

respiratory distress that required PICU admissions. Fortunately, all patients survived.

HBoV has been detected in nasopharyngeal aspirates, bronchoalveolar lavage, blood, stools and urine samples derived from children worldwide. In our patients, specimens consisted of nasopharyngeal aspirates taken at admission. Influenza A/B virus, Parainfluenza virus types 1- 4, RSV A/B virus, Rhinovirus, Coronavirus (HKU1, OC43, NL63, 229E), Human Bocavirus, Enterovirus, Parechovirus, Adenovirus, Human Metapneumovirus and SWH1N1 virus were investigated in nasopharyngeal aspirates in all patients. Presence of HBoV1 in nasopharyngeal aspirates did not correlate with gender [14]. In a study, proportion of males was higher in HBoV single infection, and co-infections were more frequent in females [9]. Conversely, our first and second patients were male with co-infection and the last one was girl with single infection.

HBoV is considered as an “emerging viral pathogen” because it is only proven to be associated with infections but not yet proven to be a cause of them. However, we aimed to emphasize this virus may cause a severe infectious disease among pediatric patients who subsequently develop acute respiratory failure and required mechanical ventilation support.

Declaration of Conflicting Interests: The authors declare that they have no conflict of interest.

Financial Disclosure: No financial support was received.

REFERENCES

- Allander T, Tammi MT, Eriksson M, Bjerkner A, Tiveljung-Lindell A, Andersson B. Cloning of a human parvovirus by molecular screening of respiratory tract samples. *Proc Natl Acad Sci U S A* 2005;102:12891-6.
- Broccolo F, Falcone V, Esposito S, Toniolo A. Human bocaviruses: Possible etiologic role in respiratory infection *J Clin Virol* 2015;72:75-81.
- Martin ET, Kuypers J, McRoberts JP, Englund JA, Zerr DM. Human Bocavirus 1 Primary Infection and Shedding in Infants. *J Infect Dis* 2015;212:516-24.
- Ziyade N, Sirin G, Elgormus N, Das T. Detection of Human Bocavirus DNA by Multiplex PCR Analysis: Postmortem Case Report. *Balkan Med J* 2015;32:226-9.
- Moreno B, Abrego L, Carrera JP, et al. Detection of Human Bocavirus Type 1 infection in Panamanian children with respiratory illness. *J Med Virol* 2015;88(3):389-94.
- Hengst M, Hausler M, Honnef D, Scheithauer S, Ritter K, Kleines M. Human Bocavirus-infection (HBoV): an important cause of severe viral obstructive bronchitis in children. *Klin Padiatr* 2008;220:296-301.
- Alam MM, Khurshid A, Shaukat S, et al. Human bocavirus in Pakistani children with gastroenteritis. *J Med Virol* 2015;87:656-63.
- Brieu N, Guyon G, Rodiere M, Segondy M, Foulongne V. Human bocavirus infection in children with respiratory tract disease. *Pediatr Infect Dis J* 2008;27:969-73.
- Calvo C, Garcia-Garcia ML, Pozo F, et al. Respiratory Syncytial Virus Coinfections With Rhinovirus and Human Bocavirus in Hospitalized Children. *Medicine* 2015;94(42):e1788.
- Shi T, McLean K, Campbell H, Nair H. Aetiological role of common respiratory viruses in acute lower respiratory infections in children under five years: A systematic review and meta-analysis *J Glob Health* 2015;5(1):010408.
- Ghietto LM, Majul D, Ferreyra Soaje P, et al. Comorbidity and high viral load linked to clinical presentation of respiratory human bocavirus infection. *Arch Virol* 2015;160:117-27.
- Korner RW, Soderlund-Venermo M, van Koningsbruggen-Rietschel S, Kaiser R, Malecki M, Schildgen O. Severe human bocavirus infection, Germany. *Emerg Infect Dis* 2011;17:2303-5.
- Edner N, Castillo-Rodas P, Falk L, Hedman K, Soderlund-Venermo M, Allander T. Life-threatening respiratory tract disease with human bocavirus-1 infection in a 4-year-old child. *J Clin Microbiol* 2012;50(2):531-2.
- Wu JJ, Jin Y, Lin N, et al. Detection of human bocavirus in children with acute respiratory tract infections in Lanzhou and Nanjing, China. *Biomed Environ Sci* 2014;27(11):841-8.